



CASE REPORT

Rectal Prolapse in An Emu (*Dromaius Novaehollandiae*): A Case Report

AKINRINMADE, J.F and EYAREFE, O.D

Department of Veterinary Surgery and Reproduction, University of Ibadan, Nigeria Correspondence: od.eyarefe@gmail.com

INTRODUCTION

Rectal prolapsed is the protrusion of all layers of the rectum through the anal orifice as an elongated cylindrical mass (Aronson 2003). It usually occurs in patients secondary to tenesmus from urogenital or anorectal disease. It has been reported in small animals with no record of breed or sex predisposition, although an observation of a higher incidence in younger animals has been made (Burrows and Ellison, 1991). In small animals the condition is associated with gastrointestinal parasitism, typhlitis, colitis, proctitis, tumors, rectal foreign bodies, and urolithiasis (Burrows and Ellison, 1990; Aronson 2003). In birds, especially emus and ostriches, the condition has been associated with cryptosporidiosis (Bezuidenhout et al., 1993; Penrith and Burger, 1993; Penrith et al., 1994; Behzadi et al., 2009), *Aspergillus flavus* and *Candida albicans* induced enteritis (Saez et al., 1979; Huchzermeyer, 1999) and immunosuppression due to the quality of feed, water and hygiene (Behzadi et al., 2009).

Cloacal prolapse has also been linked with impaction due to poor nutrition or eating habits of the ratites (Gulbahar et al., 2000). Impaction is one of the most common problems seen in ratites, especially in farmed ostrich (Gulbahar et al., 2000). Impactions may occur at any age, but are most common in 3 to 6 months juveniles (Gulbahar et al., 2000). Birds with partial impaction may present with a chronic history of lethargy, anorexia with evidence of weight loss, with pelletized feces, and at presentation are weak with persistent tenesmus leading to cloacal prolapse (Gulbahar et al., 2000). Ostrich and emu farming are still relatively new in Nigeria. Farmers keep ratio of two to twelve young or adult ostriches and emus in farms. This paper reports a case of rectal prolapse in a young emu which to the authors' knowledge is the first in this environment.

KEY WORDS: Rectal prolapse, Emu, Nigeria

CASE REPORT

A young female emu *Dromaius nonaehollandiae* was presented at the surgery clinic of the

Veterinary Teaching Hospital, University of Ibadan, Nigeria, with a history of persistent straining and diarrhea and protrusion of a cylindrical tissue from the cloaca (Figure 1). The owner could not provide information on anti-parasitic medication, but said the birds were fed on chicks' growers rations.

Examination and diagnosis: an elongated cylindrical mass protruding from the cloaca was observed at physical examination. The prolapsed mass was mildly swollen, uniformly hyperaemic with spotted areas of congestion, ulcerations, and haemorrhage due to tissue contact with pen's floor. A lubricated probe could not be inserted deep between the prolapse and the cloacal wall excluding the presence of intussusceptions as earlier described (Aronson, 2003). Diagnosis of rectal prolapse was made, and option of manual reduction and placement of cloacal purse-string sutures was adopted.

Management: Following anesthesia with 2mg/kg xylazine and 8mg/kg ketamine, the feather around the vent were carefully plucked and the area prepared for aseptic surgery. The prolapsed mass was cleared of debris with physiological saline flush, and terry towel soaked in cold physiological saline was wrapped around the prolapsed tissue to reduce swelling as earlier described (Aronson, 2003). The tissue was then lubricated with K-Y jelly and carefully manipulated into the abdomen (Figure 2). A temporary purse string suture was placed around the cloaca with 2-0 polypropylene suture material. The bird recovered smoothly from anaesthesia, and was discharged to the owner with further instruction on postoperative care and representation for clinical check-up.

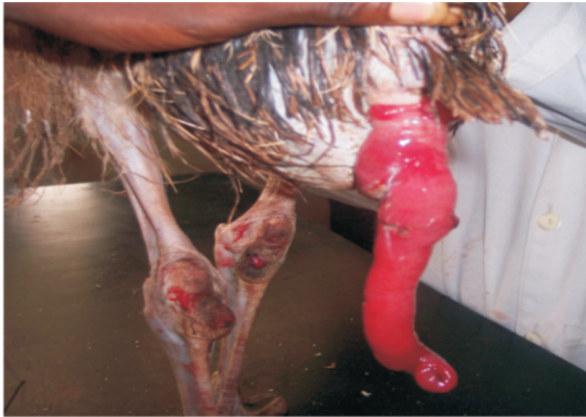

Figure 1: Emu showing prolapsed intestine

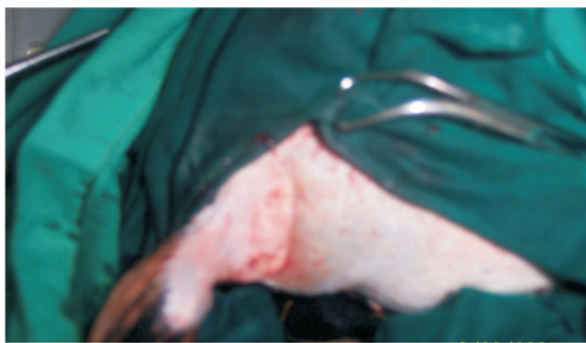


Figure 2 : Emu showing the vent after treatment

DISCUSSION

The Emu (*Dromaius nonaehollandiae*) is the survivor of at least three species of *Dromaius* that historically inhabited Australia and adjacent small islands (Jensen and Johnson 1992; Drenowatz, 1995). They are second in size to the ostrich. The females are slightly darker than the males and have more blue coloration of the face and neck (Fowler and Miller 2003). The ever increasing world demand for ostrich and emu meat, leather and feathers has been responsible for the tremendous growth of the industry worldwide. In Nigeria emu meat is a delicacy, and emu rearing is a symbol of affluence. Consequently, there has been a corresponding increase in veterinary service demand, which constitute a challenge to the modern day veterinarian who must continue to demonstrate a basic understanding of the medicine and surgical techniques in management of conditions of such exotic species in an effort to offer high quality professional services to the producers.

The emu has the shortest digestive tract of the three common ratite. Food passage through the

gastrointestinal tract takes only six to eight hours (Tully and Shane 1996, Foller and Miller 2003). Besides, the digestive system is modified for digestion of high quality plants items, large quantity of insects, small vertebrates and grasses (Fowler, 1991). As hind gut fermenters, it relies on the hind gut microflora for digestion of its high fibrous diet (Fowler and Miller 2003). These anatomical peculiarities coupled with the mode of nutrition and the shorter intestinal tract compared with other common ratites (Tully and Shane 1996, Fowler and Miller 2003) makes digestive tract disorders a common indicator for surgical intervention in this species. Information obtained from the case in question suggests nutritional inadequacy and lack of anthelmintic prophylactic medication as probable risk factor in the etiopathogenesis of the condition. Fatal prolapse and, or intussusceptions has been reported in association with impaction and heavy parasitic infection in ostriches (Honnas, 1991, Fowler and Miller 2003).

The diagnosis of rectal prolapse and or intussusception is known to be straightforward, as physical examination often shows the presence of a protruding intestinal mucosa from the anal orifice (Fossum *et al.*, 2002; Aronson, 2003). However, differentiation of rectal prolapse from intussusceptions, or elimination of the presence of the later is done by inserting a lubricated finger or probe between the protruded mass and the anal wall, which is possible to the depth of 5-7cm in intussusceptions, and not in rectal prolapse (Fossum *et al.*, 2002; Aronson, 2003). The adoption of this method confirmed a rectal prolapse in this case. The management methods adopted in this case was dictated by the quick presentation and viability of the prolapsed intestinal segments. The use of physiological saline lavage, massage and lubrication has been advocated in manual reduction of prolapsed viable rectal tissues (Fossum, 2002; Aronson, 2003). In this case, a cold saline lavage and massage was adopted to slow down the prolapsed intestinal tissue inflammatory process and concomitant vasodilatation, and to allow for easier manual reduction. A slow, gentle, and patient manipulation of the tissue with K-Y jelly lubrication as well as the intestinal smooth muscle relaxation effects of the anaesthetic protocol facilitated the reduction process. The

placement of purse-string sutures tight enough to maintain prolapsed reduction without interfering with passage of soft stool was conventional for the procedure (Fossum *et al.*, 2002). Amputation is however indicated when the prolapsed tissue is swollen, friable, and non viable and does not permit manual reduction (Perelman, 1991).

Emu chicks like ostriches may be successfully reared on most substrates if introduced immediately after hatching, but will frequently develop proventricular impaction if transferred to an unfamiliar substrate after only a few weeks of age. With inadequate nutrition, chicks are much more prone to ingesting inappropriate materials that eventually result in gastro-intestinal derangement and abnormalities. Presently, there is a dearth of information on the nutritional requirements of emu in this environment. Most formulations are based on extrapolations from poultry and may not necessarily meet the needs of these birds. The lack of crop in emus and their behavioral uniqueness of pecking at, and ingesting every object they encounter further predispose them to impaction and other gastro- intestinal disorders (Fowler and Miller 2003).

With the rapidly expanding emu industry, more research attention needs to be accorded the nutritional and health needs of emus and ostriches to enhance optimum productivity.

REFERENCES

ARONSON, L., (2003): Rectum and anus. In Textbook of Small Animal Surgery 3rd ed (Douglass Slatter) Saunders Elsevier science. 686-68794.
 BEHZADI M. A., RAZAVI S. M., YAZDANPOOR H, MIRZAEI A., TAMADON A. JAVDANI GANDOMANI,

M. (2009): Epidemiology of *cryptosporidium* infection in Ostriches (*struthio camelus*) in Iran. *Bulgarian Journal of Veterinary Medicine* **12**(1): 55- 61.
 BEZUIDENHOUT, A. J., M. L. PENRITH & W. P. BURGER (1993): Prolapse of the phallus and sewer in the ostrich (*Strhutio camelus*). *Journal of South African Veterinary Association*, **64**: 156- 168.
 BURRROW, C. F and ELLISON, G.W. (1991): Recto-anal diseases . In Ettinger SJ (ed): Text book of Veterinary Internal Medicine, 3rd ed. WB Saunders Philadelphia. 1559.
 DRENOWATZ C , (1 9 9 5) Ratite encyclopedia ,San , Antonio Ratite records Inc .
 FOSSUM T . W . CHERYL S . H . et al. (2 0 0 2) : Rectal prolapse ,In Text book of small animal surgery . 2nd ed Elsevier science Morsbyinc . 3 8-13 8 .
 FOWLER M.E. (1991): Comparative Clinical Anatomy of the Ratites. *Zoo and Wild Life Medicine* 22: 204.
 FOWLER M.E AND MILLER R.E (2003): *Zoo and Wild Animal Medicine* Fifth ed. Saunders Elsevier Science. 94-99.
 GULBAHAR M Y, AGAOGLU Z, BIYIK H YUKSEK N (2000): Zygomycotic proventriculitis and ventriculitis in ostriches (*Struthio camelus*) with impaction. *Australian Veterinary Journal*. **78**(4): 247-249,
 HONNAS, C. (1991): Proventriculotomy to relieve foreign impaction in Ostriches. *J. Am. Vet Med. Assoc* 199:461.
 JENSEN J.M, JOHNSON J.H,WEINER S.T (1992): Husbandry and medical management of ostriches ,emu, rheas, College Station Texas, wild life and exotic animals teleconsult.
 PERELMAN, B. (1991): Proceedings, 3rd Annual Conference Ostrich Med Surgery college Station, Tx, Texas, A&M University.
 SAEZ H, RINJARD J, AND STRAZIELLE L (1979): Simultaneous *Aspergillus flavus* and *Candida albicans* infection, and rectal prolapse, in a young emu born in captivity. *Recueil de Medecine Veterinaire*; **155**(9): 689-692.
 TULLY TN and SHANE SM. (1996): Ratite management, medicine, and Surgery, ed 1, Melbourne, Florida, Krieger Publishing.